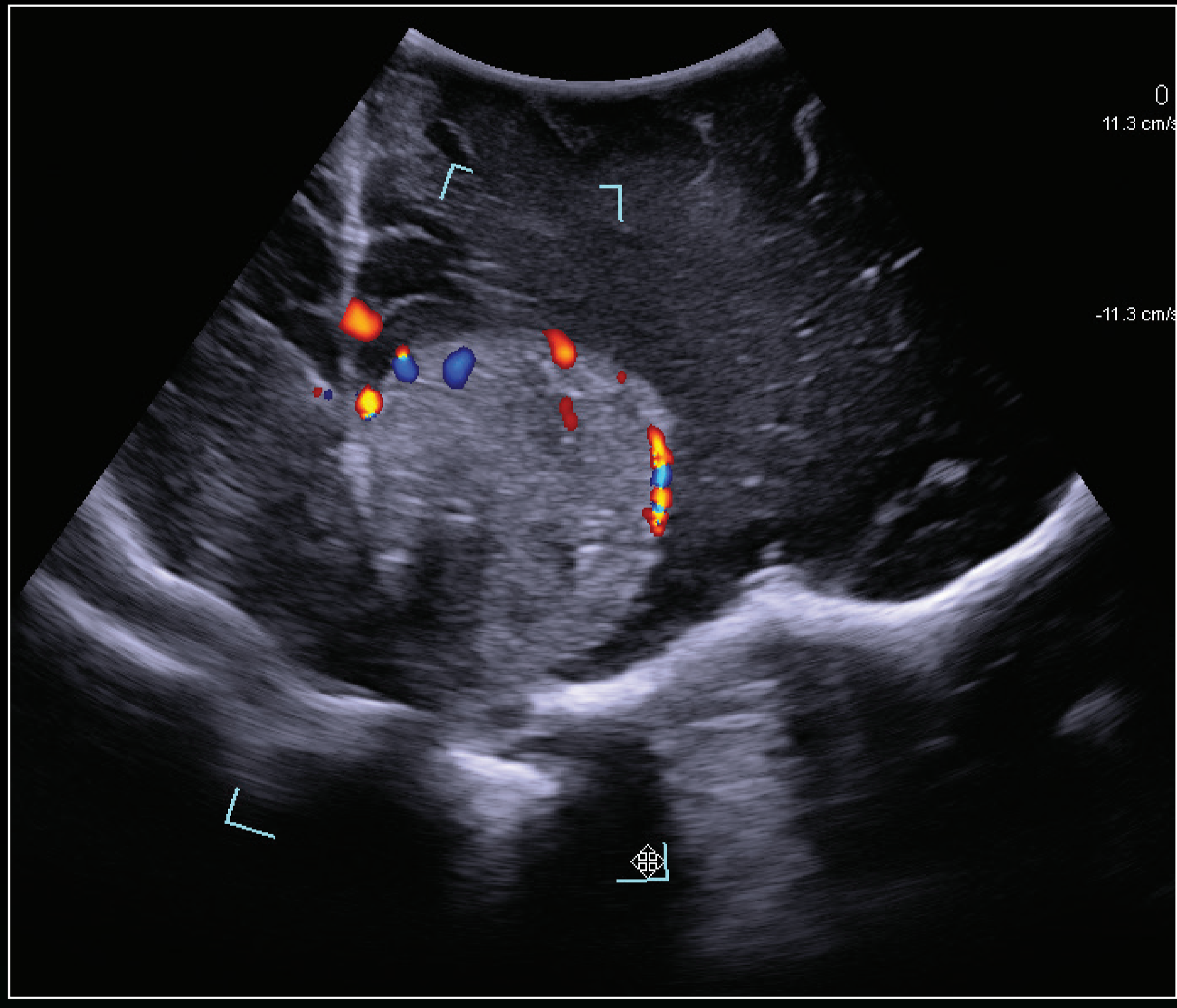
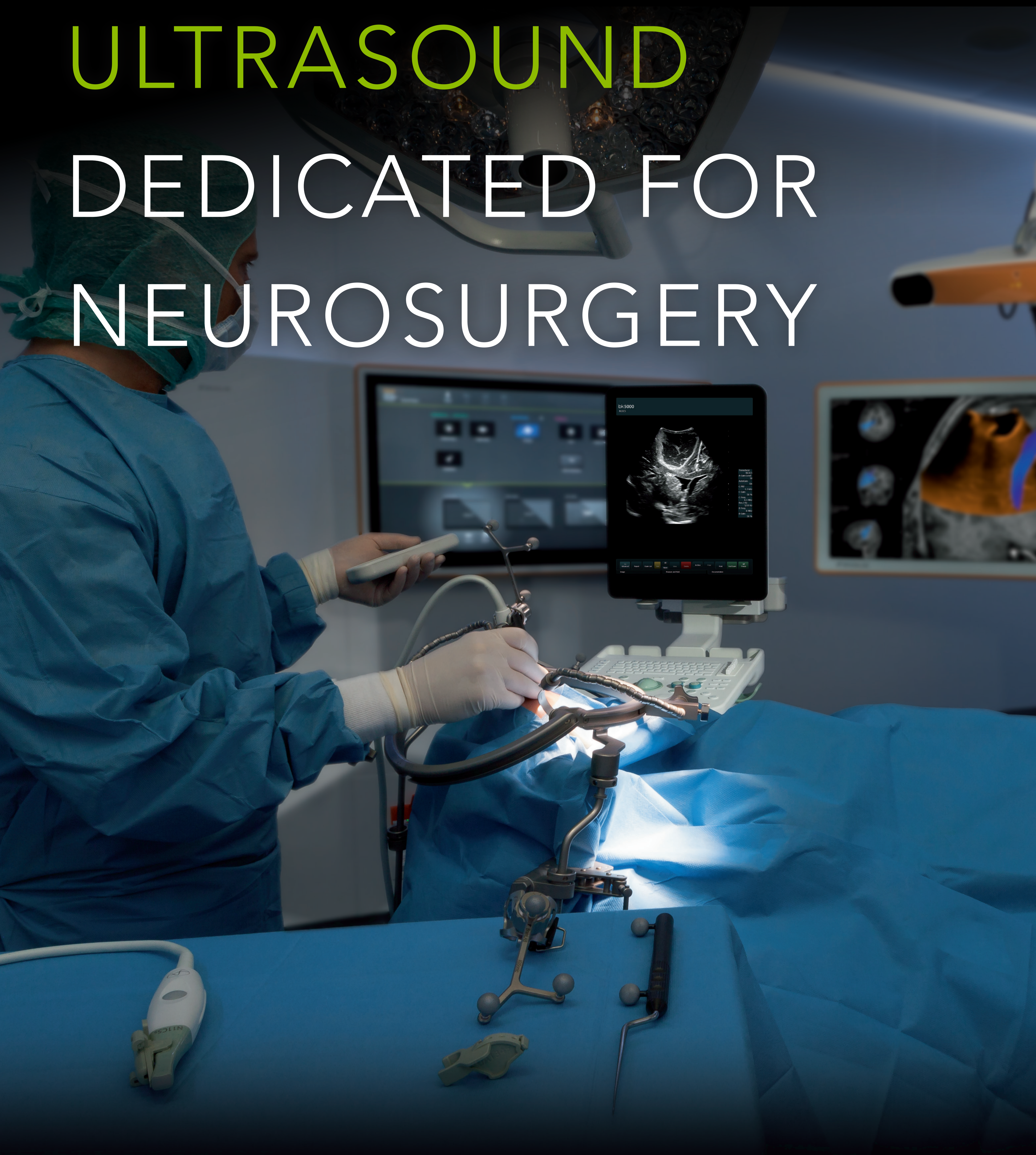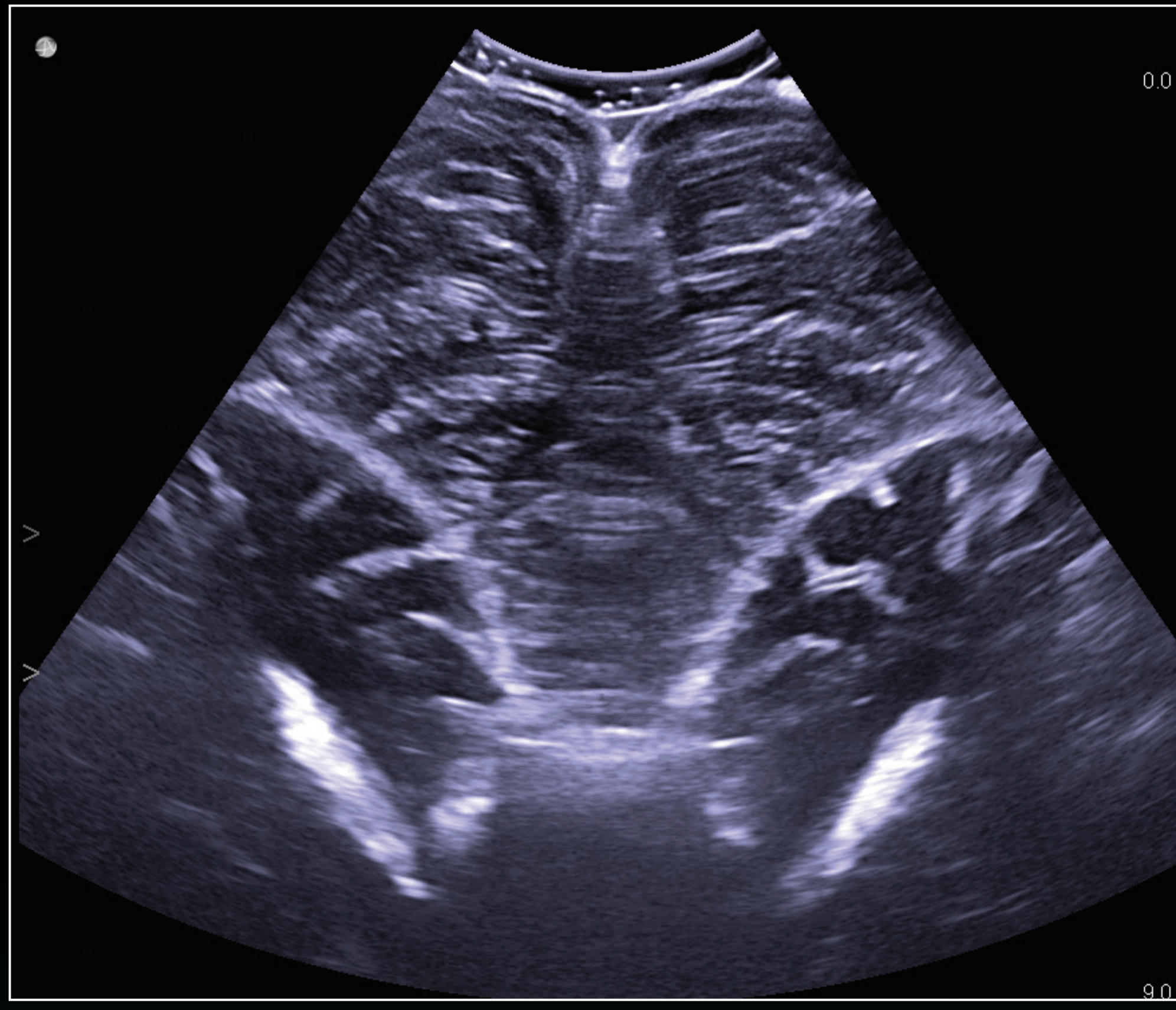


bk   
medical

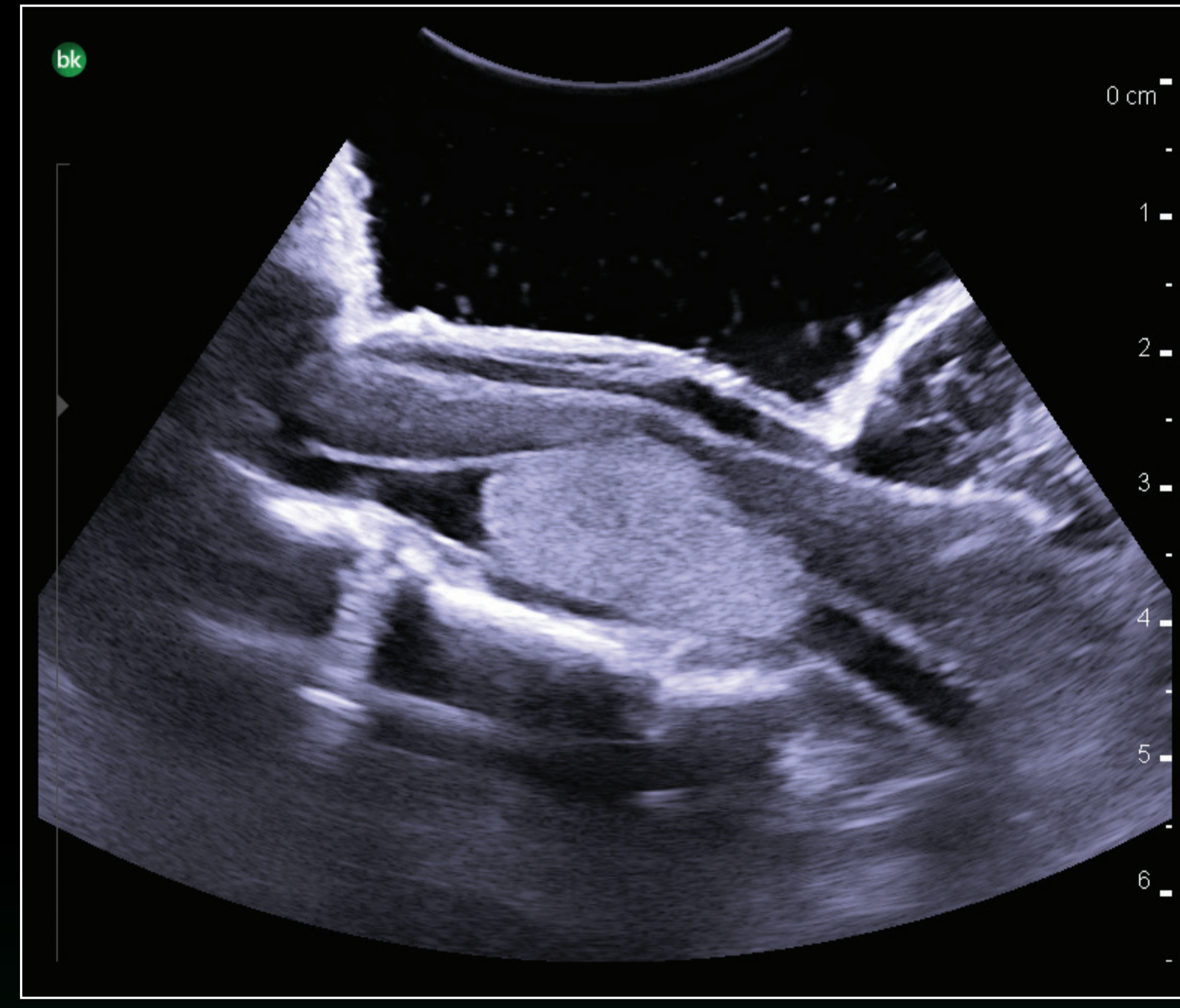
ULTRASOUND  
DEDICATED FOR  
NEUROSURGERY



Falx meningioma with color Doppler



Highly-detailed brain tissue



Benign spinal cord lesion - sagittal plane

as specialized as you